

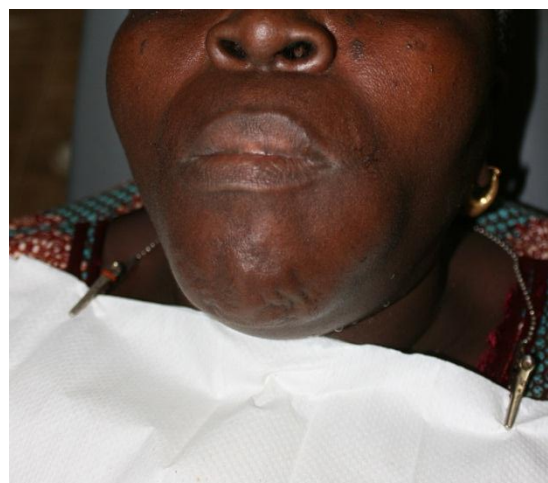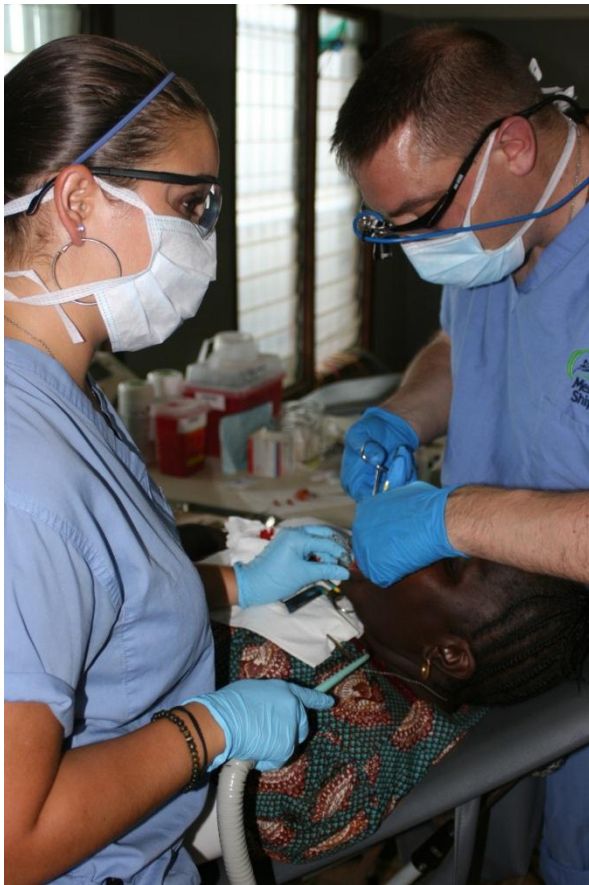Day 7 – and the lady we cut up

We also did lots of interesting surgery today.

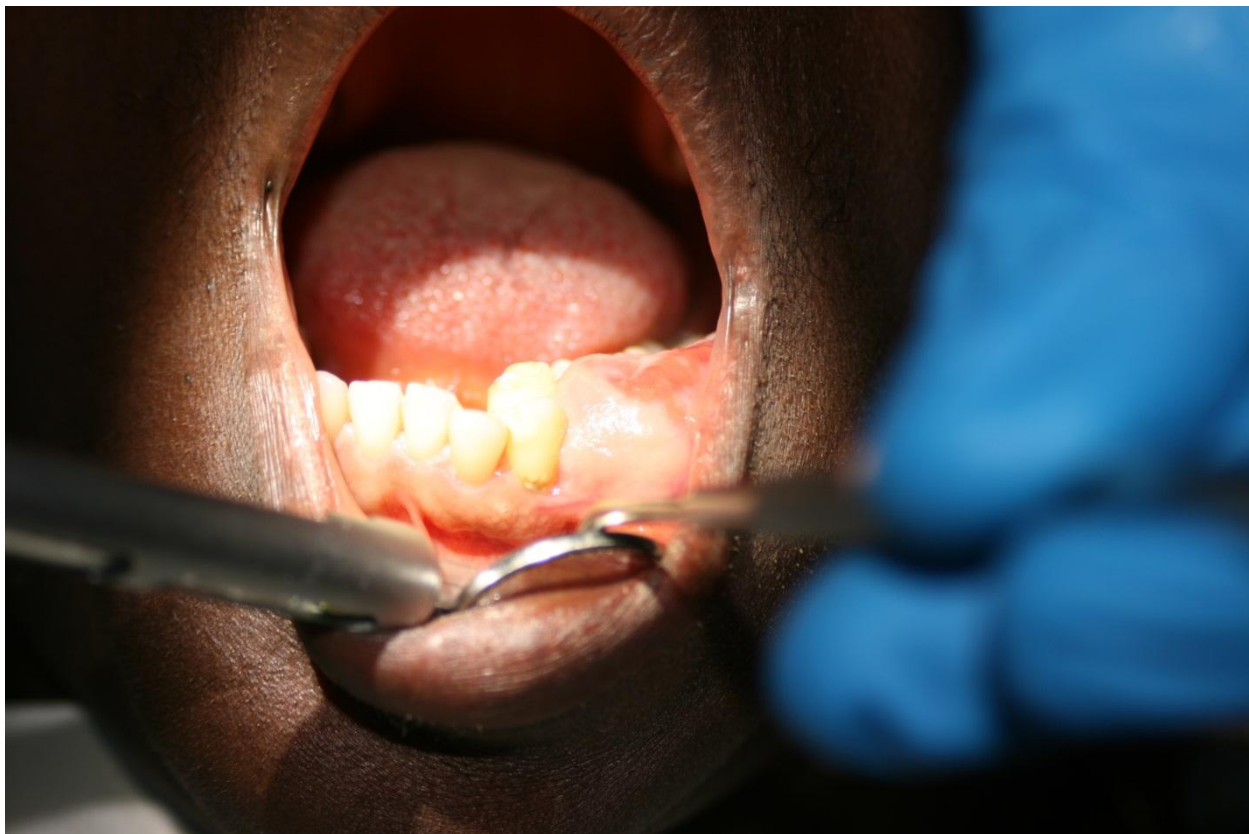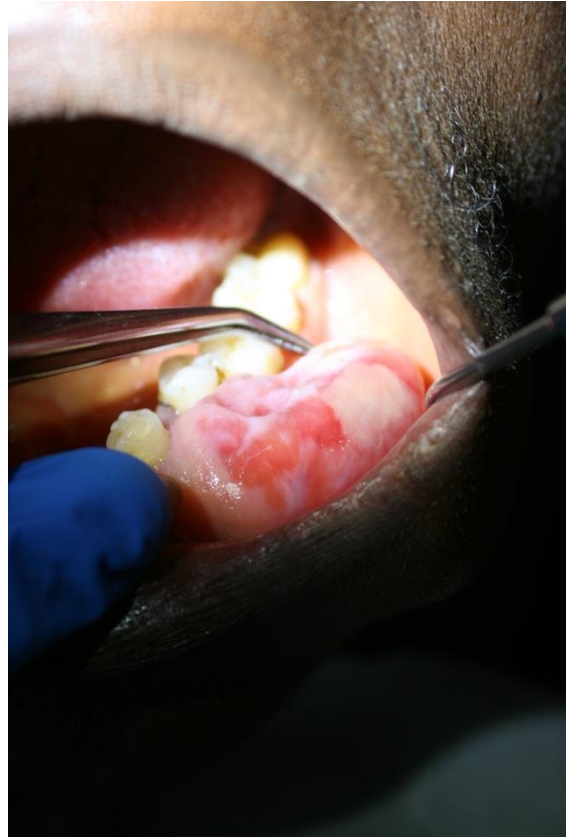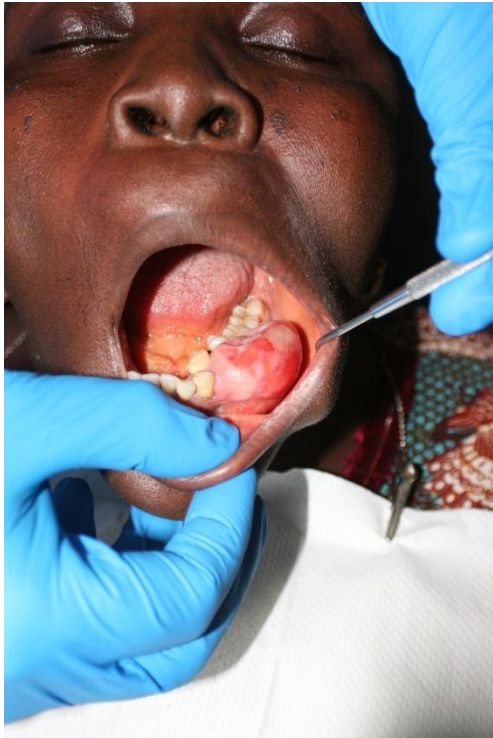I had four other patients with trismus similar to the man on Friday who we were able to help and lady with a pathologically fractured mandible secondary to a osteomyelitis from a lower wisdom tooth who we weren't.

My last patient of the day was happy to have some pictures taken so here's the report.

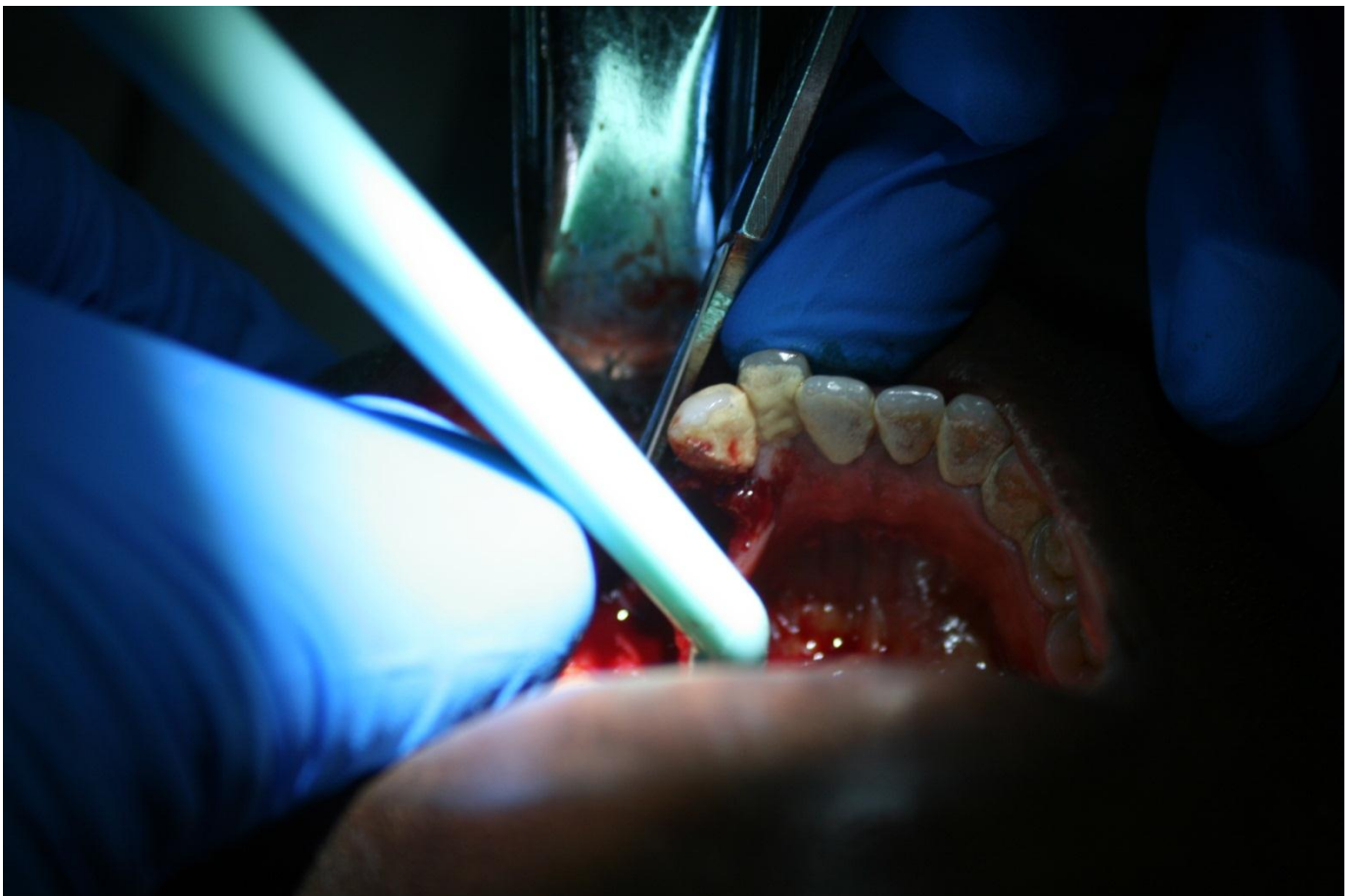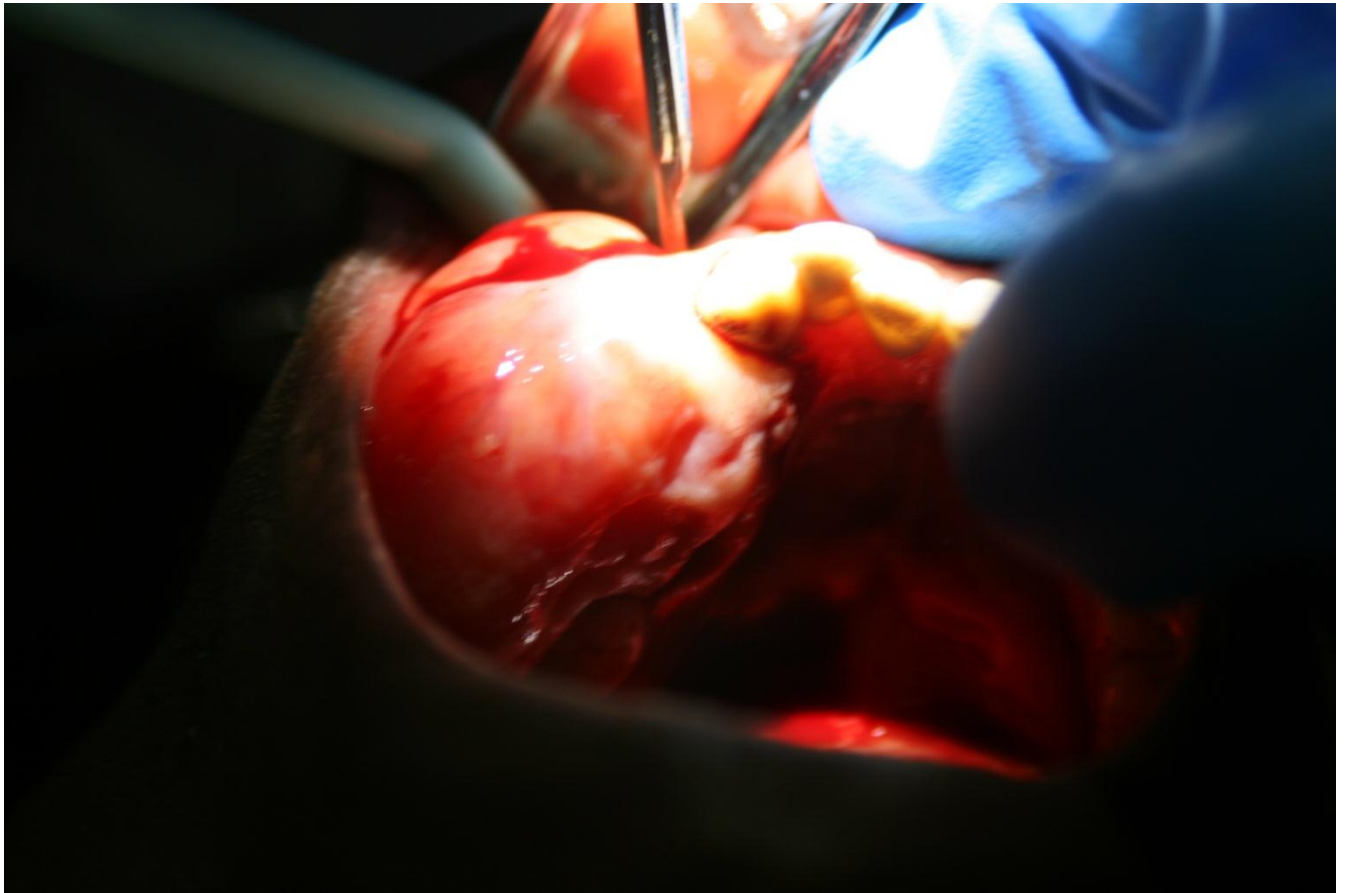
She presented complaining of a painful swelling on the lower left side of her mouth for the last 3 years or more.

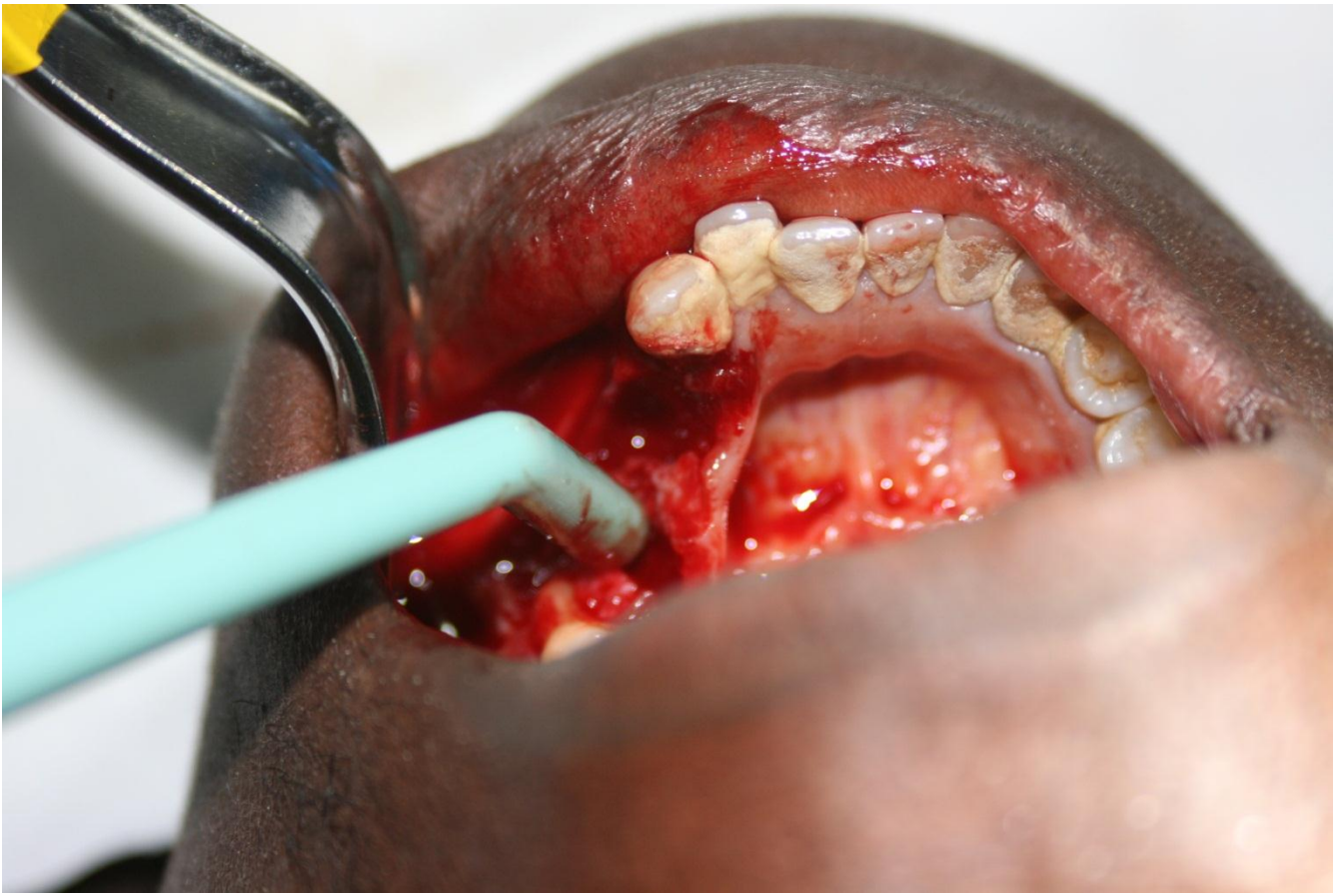

In the mouth she looked like this

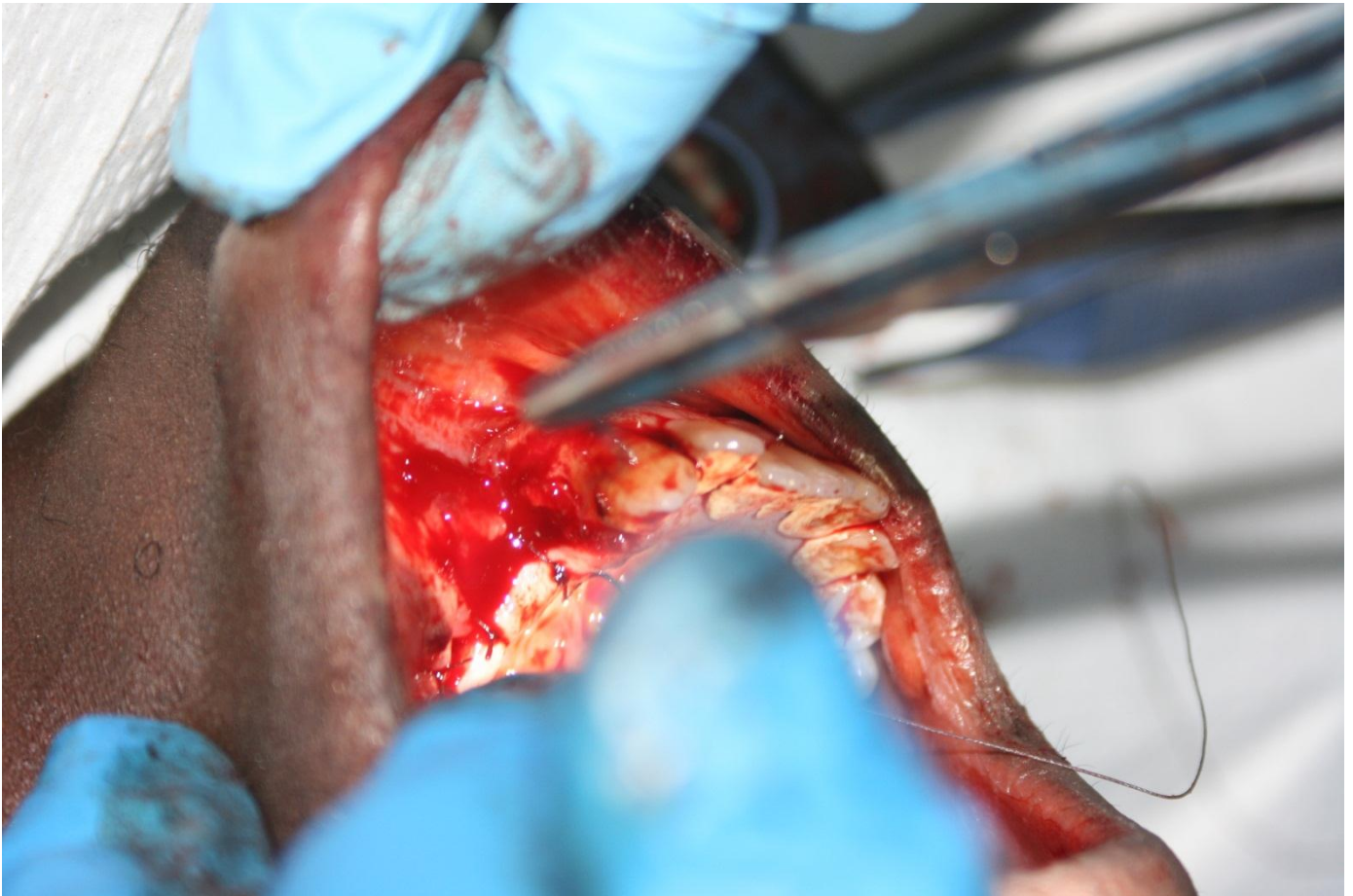


So we numbed it up and cut it out

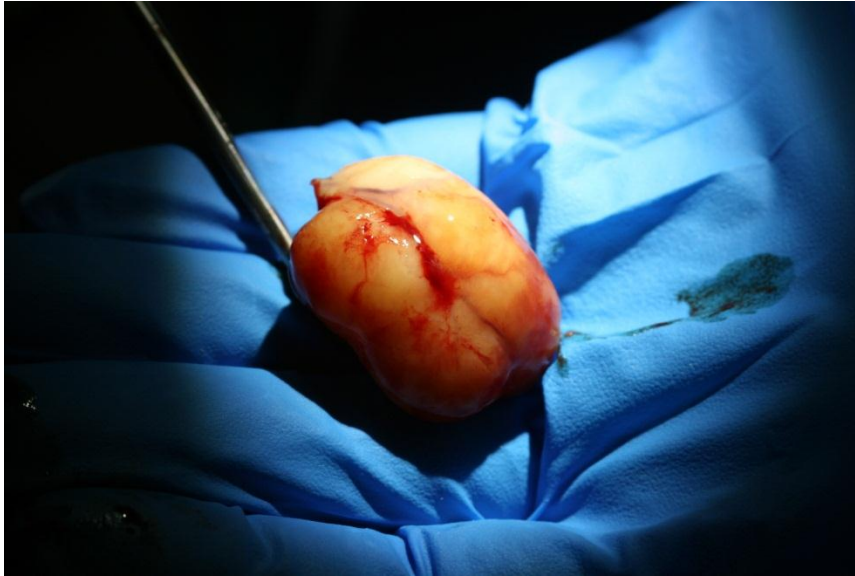




And stitched her back together



This is what came out of her



And this is how she was at the end of it.

